

Evaluation of post-extraction alveolar regeneration time in advanced periodontal disease employing novel hydroxyapatitepolymeric (FlexiOss®Vet) in dogs

©ANNA MISZTAL-KUNECKA¹, ©STANISŁAW DZIMIRA², ©ANNA ŁOJSZCZYK³

¹Veterinary Clinic DentalVet Anna Misztal-Kunecka,Szczecin, Poland

²Department of Pathology, Division of Pathomorphology and Veterinary Forensics, Faculty of Veterinary Medicine, Wrocław University of Environmental and Life Sciences,Wrocław, Poland

³Department and Clinic of Animal Surgery, Laboratory of Radiology and Ultrasonography, University of Life Sciences in Lublin,Lublin, Poland

Received 14.12.2023

Accepted 26.01.2024

Misztal-Kunecka A., Dzimira S., Łojczyk A.

Evaluation of post-extraction alveolar regeneration time in advanced periodontal disease employing novel hydroxyapatitepolymeric (FlexiOss®Vet) in dogs

Summary

The purpose of the study was to demonstrate bone regeneration and the time of formation of new alveolar bone based on implanted FlexiOss®Vet bone substitute material. The study attempted to determine the time taken to fill bone defects with newly formed osseous bone compared to alveoli with a standard method of filling the post-extraction alveolus with a collagen sponge. The study was conducted on a group of 12 dogs with advanced periodontal disease (stage IV) in which polymeric hydroxyapatite bone substitute material (FlexiOss®Vet) was implanted into alveoli on the right side, and collagen sponge was implanted into alveoli on the left side in the same patient. The patients underwent macroscopic inspection and X-ray examination at different periods of regeneration after the procedure. On the right side, macroscopically, the alveoli showed features of marked enlargement, and on X-ray examination they gave opacity to X-rays and there was no clear border between the alveolus and alveolar bone. On the left side, the alveoli were clearly penetrable to X-rays, and hollow alveoli filled mainly with connective tissue were observed. The study also showed a significant reduction in bone healing time in alveoli with implants compared to self-healing alveoli. These results suggest that the implanted material is significantly beneficial in the process of bone regeneration in large bone defects in dogs and notably shortens the process of bone regeneration after tooth extractions. It is presumed that this could reflect a model for the treatment of large bone defects in not only the maxilla and mandible, but also long bones, and that it could be a model for alveolar healing in humans.

Keywords: bone regeneration, dog, alveolar socket, osseous defects, hydroxyapatitepolymer, curdlan

The alveolar process is a tissue that develops as the teeth grow. The volume and shape of the alveolar process mainly determines the shape of the teeth, their axis of eruption and inclination (27). Periodontal disease is the most common indication for tooth extraction in canine dentistry. Epidemiological studies show that 80% of dogs over two years of age suffer from periodontal and dental disease (1). On clinical examination, in stage IV periodontal disease, there is vertical atrophy of the alveolar bone, severe gingivitis and periodontitis, loosening of stage II and III teeth, development of numerous pathological pockets and formation of stage II and III furcations. On radiographic examination, alveolar bone atrophy, numerous pathological pock-

ets and numerous periapical lesions within the roots of the teeth are observed. The only way to treat such advanced periodontal disease is a numerous extraction of a large number of teeth. Increasingly, alveolar bone atrophy is observed in clinical practice after extractions performed on young patients (26). This is particularly evident in small and miniature breeds of dogs, although we can also encounter it in large breeds showing predisposition (e.g. Labradors – about 57%) (36). After complete extraction of the dentition in dogs, the alveolar bone is not prosthetically supplied, as it is in human dentistry. After the procedure, owners often feed the dog only soft food, so that the animal is not forced to chew the food. Thus, the bone does not work

and begins to undergo slow lysis – this is known as functional atrophy.

Clinical and radiographic studies conducted to date have shown that pronounced changes in the height and width of the alveolar process occur after both single and multiple tooth extractions (5, 16). The process leading to bone reduction is more pronounced in the initial phase of wound healing than in later periods after tooth extraction. Most of the dimensional changes, both horizontal and vertical of the alveolar process, take place during the first three months of healing (19). The greatest atrophy occurs in the buccal wall of the alveolus, due to the loss of its physiological function. The buccal alveolar compact lamina, whose function is to anchor the tooth, is no longer needed and reduces in size when the tooth is removed. Data available in the literature report atrophy of the alveolar bone vertically by 11-22% and from 26.7 to as much as 62.4% of the alveolar width in the first period after tooth extraction, i.e. 2-7 months. Afterwards, the rate of atrophy decreases to about 1% per year (26). For this reason, cases of pathological fractures after tooth extraction have been reported in dogs with moderate to advanced periodontitis. Previous studies have shown that the incidence of pathological mandibular fractures in dogs is related to the first mandibular molars.

To prevent pathological fractures after extraction, if possible, the extraction should be performed with a technique that is as minimally traumatic to the tissues as possible, and additional procedures such as bone grafting or filling the alveolus with bone substitute material should be performed. To make sure that the bone after tooth extraction does not continue to recede, the alveolus after tooth extraction should be regenerated. Developments in veterinary dentistry should prompt veterinarians to think more deeply and take additional measures to both protect and further preserve all elements of the oral cavity. The restoration of the alveolus and alveolar process after tooth extraction should therefore in fact be a mandatory procedure to preserve the height and width of the alveolus. Collagen sponge is a commonly used material for filling post-extraction alveoli. It is a highly effective, resorbable, natural porcine-derived type 1 collagen that provides rapid absorption and high biocompatibility. The strong haemostatic effect allows for shorter treatment times and promotes wound healing by stabilising the clot, accelerating epithelialisation and revascularisation. However, the use of a collagen sponge does not inhibit alveolar bone atrophy, so the use of a bone substitute material is necessary to prevent it.

One of the most appreciated bone fillers due to its biocompatibility, lack of carcinogenic properties and high resistance to sterilisation processes is hydroxyapatite. There are many commercially available bone graft materials based on biological and synthetic hydroxyapatite (29). Hydroxyapatite in porous form can not only serve as a bone filler, but can also be used as a carrier

for active substances such as antibiotics (33). The use of hydroxyapatite alone due to its poor resorption, low resistance to fracture and long-lasting bonding to host cells made it necessary to find a solution to improve the properties of hydroxyapatite and its remodelling in bone tissue (23). This result was achieved by using polymers and ceramics. The disadvantage of ceramic-containing materials is their shape. They often come in the form of granules, which are difficult to implant in bone defects, and in the form of hard pellets, which are difficult to fit into the implant site. (10) The solution to improve these properties of hydroxyapatite is to combine it with a polymer, which significantly reduces this disadvantage. The polymers used are mostly of animal origin, so the need for thorough purification (due to the high risk of transmitting infections such as viruses) necessitates a high product price. To solve the above-mentioned problems, B-glucan, which is a relatively cheap and non-animal-derived substrate, was used as the polymer phase.

The formulation used in the study, FlexiOss[®]Vet, is a mouldable biomaterial produced from calcium phosphate (hydroxyapatite of synthetic origin) and curdlan (a glucan polysaccharide composed of glucose). It has no cytotoxic or carcinogenic effects, and due to its bioactivity it bonds directly to bone and stimulates osteogenesis. The purpose of this study was to determine the time of bone reconstruction of the alveolar processes based on the implanted bone substitute FlexiOss[®]Vet and to demonstrate the effectiveness of the tested material in the healing process of extensive alveolar lesions, thereby preventing alveolar bone atrophy after tooth extraction. FlexiOss[®]Vet has previously been used in animals, but the studies carried out did not provide a detailed answer to the question of the time taken for the bone defect to fill after implantation of the material and were merely a confirmation of the effectiveness of the biomaterial tested. The second preparation tested, Surgispon, is commonly used in dentistry.

Material and methods

Animals participating in the study. The study involved 12 patients – mixed breed dogs between 3 and 8 years of age, weighing between 5 and 20 kg (Average age of patients was 6.5 years, average weight of patients was 9.58 kg), healthy, without systemic chronic diseases. Given the minimal size of the study group, it was determined that 12 patients with similar oral lesions treated at comparable times would be a sufficient number to be able to draw reliable conclusions from the research. The animals involved in the study came from private owners who gave written consent for their pets to participate in the study. The procedures carried out are routinely performed on the animals and therefore no additional approval from the ethics committee was required. Patients were qualified for the procedure on the basis of a clinical examination and an oral X-ray. The two main circumstances excluding a patient from taking part in the study were medical conditions and radiological evaluation.

Tab. 1. Clinical evaluation of the oral tissues and X-ray after surgery at a specific time

		% of X-ray impermeability in alveolar sockets after extractions			Number of dogs showing the symptoms tested (% of study group)				
		Canine tooth	Incisors	Premolar and molar	Swelling of the mucosa	Congestion/bleeding on touch	Wound edges spreading, fistula formation	Exudation from the wound	Pain reaction to touch
3 rd week	Right side	90%	90%	100%	2 (16.7%)	4 (33.3%)	0 (0%)	0 (0%)	0 (0%)
	Left side	10%	0%	0%	10 (83.3%)	10 (83.3%)	2 (16.7%)	4 (33.3%)	10 (83.3%)
4 rd week	Right side	90%	100%	100%	1 (8.3%)	2 (16.7%)	0 (0%)	0 (0%)	0 (0%)
	Left side	20%	30%	50%	8 (66.6%)	8 (66.6%)	2 (16.7%)	4 (33.3%)	8 (66.6%)
5 th week	Right side	100%	100%	100%	0 (0%)	0 (0%)	0 (0%)	0 (0%)	0 (0%)
	Left side	30%	40%	80%	7 (58.3%)	7 (58.3%)	2 (16.7%)	4 (33.3%)	7 (58.3%)
6 th week	Right side	100%	100%	100%	0 (0%)	0 (0%)	0 (0%)	0 (0%)	0 (0%)
	Left side	50%	70%	100%	3 (25%)	0 (0%)	0 (0%)	4 (33.3%)	3 (25%)
7 th week	Right side	100%	100%	100%	0 (0%)	0 (0%)	0 (0%)	0 (0%)	0 (0%)
	Left side	80%	90%	100%	0 (0%)	0 (0%)	0 (0%)	0 (0%)	0 (0%)
8 th week	Right side	100%	100%	100%	0 (0%)	0 (0%)	0 (0%)	0 (0%)	0 (0%)
	Left side	100%	100%	100%	0 (0%)	0 (0%)	0 (0%)	0 (0%)	0 (0%)

Concerning the first circumstance, patients were disqualified because of the presence of chronic diseases due to the impossibility of comparing healing in healthy patients with patients who may have impaired healing due to, for example, kidney, liver or heart disease, or those taking medications that alter calcium and phosphate absorption or metabolism. Chronic diseases were also a contraindication to subjecting patients to subsequent anesthesia for radiological follow-up. Therefore, only patients whose physical status level according to the American Society of Anesthesiologists (ASA status) was not equal to or higher than ASA III were qualified for the procedure. The second disqualifying circumstance was derived from the condition of the oral cavity: if based on the clinical and radiological evaluation there was no requirement to remove the same teeth both on the right and left side, then this would make it impossible to compare the healing process of the two sides. The group of patients qualified for the study therefore included those whose lesions on both sides of the oral cavity were at a similar stage, which largely allowed observation of the time and quality of wound healing. The animal owners were informed of the procedure, but they did not know which side was being treated with bone substitute material and which side was being treated in the conventional manner. They were tasked with observing the animals (the way they took their food and any pain reactions) and were asked to make their own assessment of both sides each week after surgery (they were asked to mark the manifested symptoms in the provided table: swelling of the mucosa, bleeding on touch, congestion, whether it was covered with secretion, pain reaction to touch). The table adopts the 0-1 system; i.e. if there was discharge, it should have been marked with a “+”, regardless of what its nature was. If there was no discharge, it had to be marked with a “-”; sign. The same principle applied to the evaluation of other observations. In the study, there was no need to hide information from the attending physicians, since the clinician (AMK) carried out the observation according to the established scheme (right side – examination, left side – follow-up) and evaluated

the state of healing according to the above scheme and on the basis of cyclic X-ray examinations. The results of the clinical evaluation of the patients; oral condition and x-ray examination are shown in Table 1. Dogs with significantly advanced periodontal disease – stomatitis grade IV (according to AVDS, i.e. American Veterinary Dental Society), in which a large number of extractions were necessary, were eligible for the study, so that it was possible to compare mirrored alveoli (Fig. 1, 2). Following the clinical evaluation and X-ray examination of the teeth (photos in oblique head projection and dental X-ray of the teeth), the teeth were qualified for necessary extraction (Fig. 5).

Preparation of bone substitute material. In the test sample, FlexiOss[®]Vet was placed into the alveoli after tooth extraction (based on the data in the drug product information leaflet). The FlexiOss[®]Vet biomaterial is packaged sterile, and is plasticized with sterile saline solution to achieve plasticity and formability during implantation. For this purpose, after opening the package, the shaper was placed in a sterile container containing saline solution in an amount that completely covers the shape of the biomaterial.

Due to soaking before placing the preparation in the alveolus, it becomes malleable: it can be cut and shaped as desired. Using sterile scissors and tweezers, triangular moulds were cut and implanted in the alveoli. Taking into account the physical properties of the formulation, including its expansion and increase in volume by about 30% in 48 h, elements were used in the size of a maximum of 50% of the alveolar volume. A Surgispon collagen sponge, which was also soaked in saline and placed to fill 50% of the alveolus, was placed in the alveolus of the other treated side of the patient (considered as a control trial). This is a material commonly used in dentistry, both in humans and animals that has a haemostatic effect, and its role is to maintain the clot in the alveolus, preventing the formation of a dry alveolus. It is an agent in the form of lyophilized tampons of various sizes. It is non-toxic, anti-allergenic, non-immunogenic and non-pyrogenic. Its uniform porosity guarantees positive haemostasis.

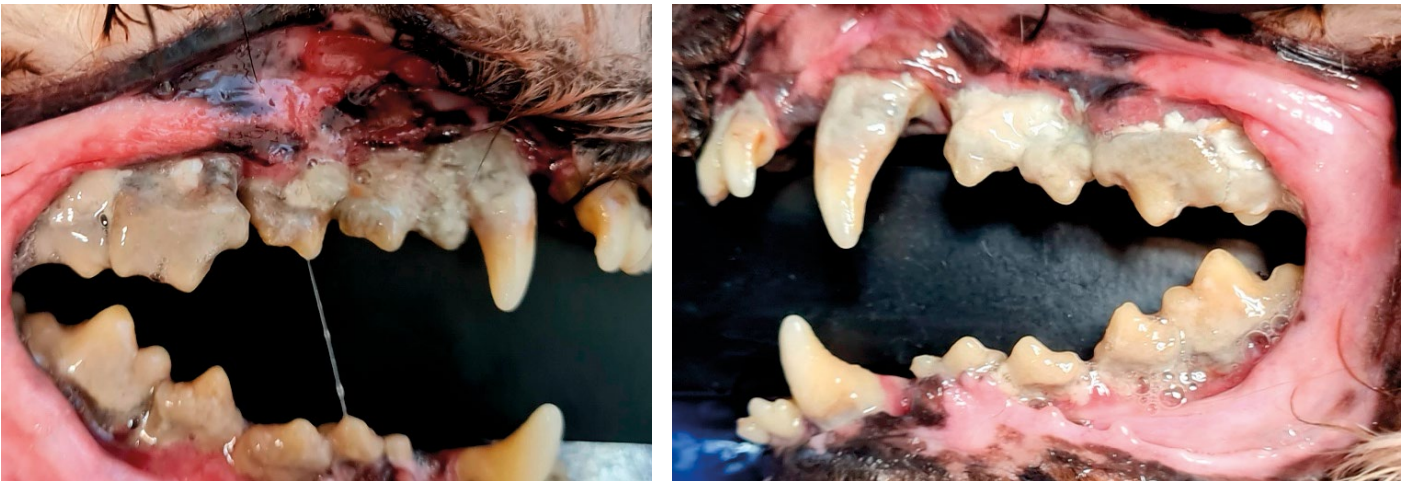

Fig. 1, 2. Condition of the oral cavity before the treatment on the right side of the mouth – all the features of stage IV stomatitis can be found here – strong recession of the gums and bone, purulent discharge from the pathological pockets, III degree furcations in multi-rooted teeth, periodontitis

Surgical procedures. Surgical procedures were performed under general anaesthesia with all principles of surgical asepsis. Patients were put under general anaesthesia based on the anaesthesia protocol developed for performing this type of procedure.

In the first stage of the procedure, the oral cavity was thoroughly cleaned of tartar and plaque using an ultrasonic scaler and polishing erasers and then rinsed with chlorhexidine solution. Tooth extraction was carried out using an open method, i.e. an incision was made in the mucosal flap, the periosteum was stripped and the bony process was removed from the buccal side, leaving the lingual/palatal wall intact. After removal of the tooth, the alveoli were lysed. On the right side, FlexiOss® Vet material was placed into the alveoli, while on the left side, the alveoli were protected in the traditional manner, i.e. with Surgispon haemostatic sponge.

The right side of the patient was considered the test group, while the left side was considered the control group of post-extraction alveoli. Lastly, enough tissue was released so that a flap could be placed over the alveolus without spontaneous retraction. The wound was sutured with 4–0 monofilament material using single sutures so that there was no tension within the healing tissue (which could result in the flap opening and the material falling out of the alveolus). As the post-surgery treatment the animals received standard antibiotic therapy and pain prevention.

Clinical and radiological evaluation. To demonstrate the timing of bone coverage of the alveoli based on the filling used, the study animals were divided into 3 groups of 4 individuals each. The first group underwent radiological follow-up at 3 and 6 weeks after surgery, the second at 4 and 7, and the third at 5 and 8 weeks after surgery.

The standard bone healing time reported in the literature assumes healing within 8 weeks (11, 17). It was assumed that alveoli that were not implanted with FlexiOss® Vet, but filled with the routinely used Surgispon collagen sponge, would also be healed at 8 weeks to allow for comparison. The bone-filling material was subjected to radiographic evaluation of healing; in addition, radiographic images of the mirrored alveoli were compared. Radiographic evaluation is used to indirectly assess bone structure and its

mechanical properties. The oral cavity was subjected to clinical evaluation (mode of alveolar healing, degree of gingival atrophy, macroscopic evaluation of healing of post-extraction wounds).

Macroscopic examination of the oral cavity was performed with a periodontometer (otherwise known as a periodontal probe): a blunt-ended, graduated instrument used to assess the periodontium, or gums and peri-gingival tissues. The scale of the periodontal probe (from 1 to 10 mm, graduated in 1 or 2 mm increments depending on the periodontometer) makes it possible to determine the depth of the pathological pocket and the degree of gingival recession. Using the probe, it is also possible to determine the degree of furcation in multi-rooted teeth and assess the state of healing of post-extraction tissues. Finally, both oral cavity sides treated differently were compared.

Results and discussion

Clinical examination on the right side, which was the test sample, revealed a marked strengthening of the mucosal structure and showed no signs of inflammation or surgical wound dehiscence. On the control (left) side, the gingiva was visibly reddened, the mucosa was soft and sensitive to touch, bleeding on touch until 5 weeks after surgery. In the follow-up sample, periodontal examination with a periodontometer showed impaired bone and gingival healing with granulation formation in many areas, which was not noted in the study sample. The bone graft material persisted throughout the study period, forming mineralized bone tissue extending from the inner implant area to the buccal and palatal sides, which represented the area of bone loss created after extraction. On the left (control) side, granulation formation and resorption of alveolar bone in the buccal area were observed.

The X-ray examination on the right side (with implanted FlexiOss® Vet) showed an X-ray impermeability of 100% of the alveoli in the 3rd week after extraction, in the small alveoli after extraction of premolars and molars (mainly short and thin roots),

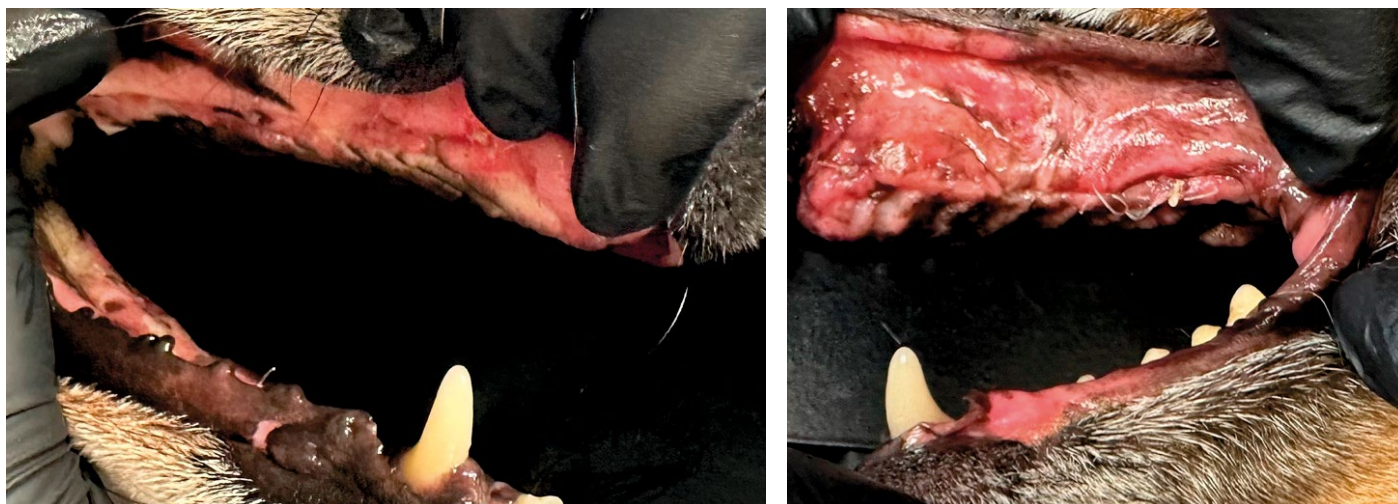


Fig. 3, 4. Oral condition 3 weeks after the procedure. On the left side – gums still reddened, tender, bleeding during periodontometer examination. Macroscopic examination shows tooth extraction sites with tissue collapse at the alveolar site. On the right side of mouth – gums well adhered to bone, no bleeding during periodontometer examination. Bone on the right side is hard, the bone plate is expanded, on the left side – in clinical assessment, the bone is soft, thin, in some places (especially after extraction of large teeth) collapsed with a reduced steepness compared to the right side

which persisted until the end of the examination. On the control side, filling of the alveoli with bone (and thus reduced radiopaque permeability) did not occur until the 4th week of the examination, filling half of the alveoli and gradually filling the alveoli with newly formed bone in the following weeks. The incisors, although not considered by clinicians difficult to extract, are nevertheless wide and long teeth. Hence, filling the alveoli with bone took place later than in the case of premolars and molars. Filling of the post-extraction alveoli with bone, and thus increasing the impermeability to X-rays, takes place in the case of the incisors at this level in week 5 (gradually increasing the impermeability from week 3 of the study from 90% to 100%) of the study in the case of the side with the FlexiOss[®]Vet implanted, while on the left side, where the collagen sponge was implanted, the process was much slower. At week 3 on

the left side, the alveolar bone was 100% transmissible to X-rays and an impermeability to X-rays of 90% did not occur until week 7 of the procedure. Full filling of the alveolus with bone did not occur until week 8 of the study. The largest tooth in the dog's jaw – and thus the tooth that will leave the largest alveolus by volume is the fang. It is the alveolus after fang extraction that best demonstrates how much implantation of bone substitute material accelerates recovery after surgery. On the right side, 100% filling of the alveolus with newly formed bone took place at 5 weeks postoperatively, while on the left side, at 8 weeks postoperatively. The healing process on the right side started very quickly: at 3 weeks after extraction, 90% of the alveolus was already filled, while on the left side, the impermeability to X-rays was only 10% and increased very slowly with each successive week of the study (Fig. 3, 4, 6, 7, 8).

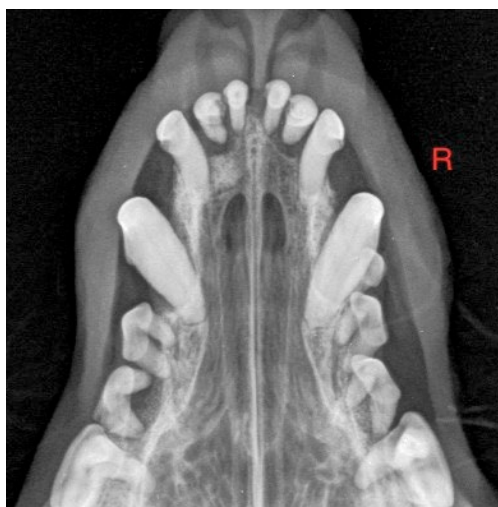

Fig. 5. Radiological evaluation before surgery – visible numerous furcations, pathological pockets and periapical lesions, in all teeth. Stomatitits IV

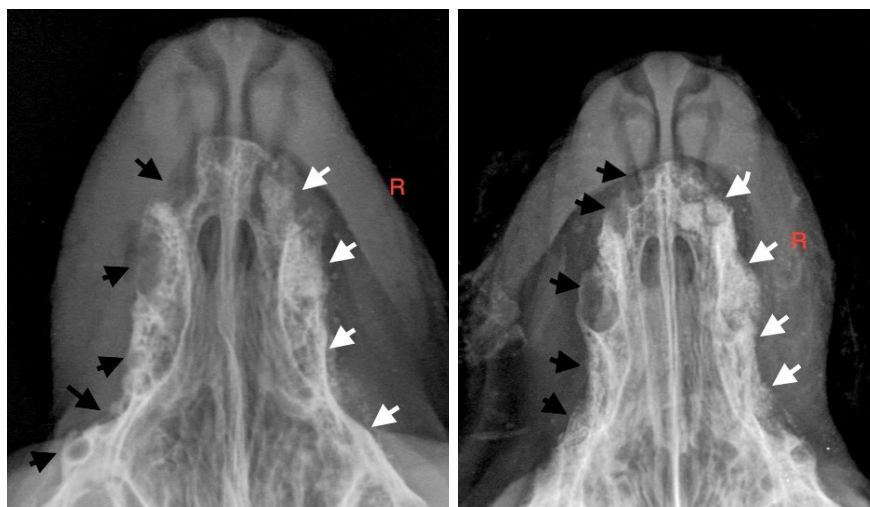


Fig. 6, 7. Radiological control at 3 weeks after surgery (6) and 4 weeks after surgery (7) – on the right side, white arrows mark areas of low X-ray permeability suggesting bone expansion at the site with implanted FlexiOss[®]Vet bone substitute material. On the left side, the black arrows mark the alveoli filled with soft tissue, with no signs of ossification

On the right side there was also no regression of the alveolar bone. On the opposite, left side, the alveoli were still penetrable to X-rays at day 21, and there was gradual atrophy of the alveolar bone. Radiological enhancement was not as strong as on the right side. Pet owners reported a significant improvement in their dog's health and well-being within 1-3 days after the procedure. On macroscopic examination, clear differences were observed between the right side of the patient, where hydroxyapatitepolymer (FlexiOss®Vet) was applied, and the left side, where only Surgispon collagen sponge was placed.

Securing the alveolar bone after extraction is an essential part of an adequate treatment. In the spontaneous healing of an alveolar wound, the local geometry regulates the function of the cells during the healing process, the flow of fibroblasts organizes the formation of collagen fibers and collagen forms lines of tension in response to moving tissues. The forces involved in healing a post-extraction alveolus can be compared to the forces acting during the pulling of a rope: myofibroblasts pull from both the buccal and palatal/lingual edges toward the centre of the alveolus.

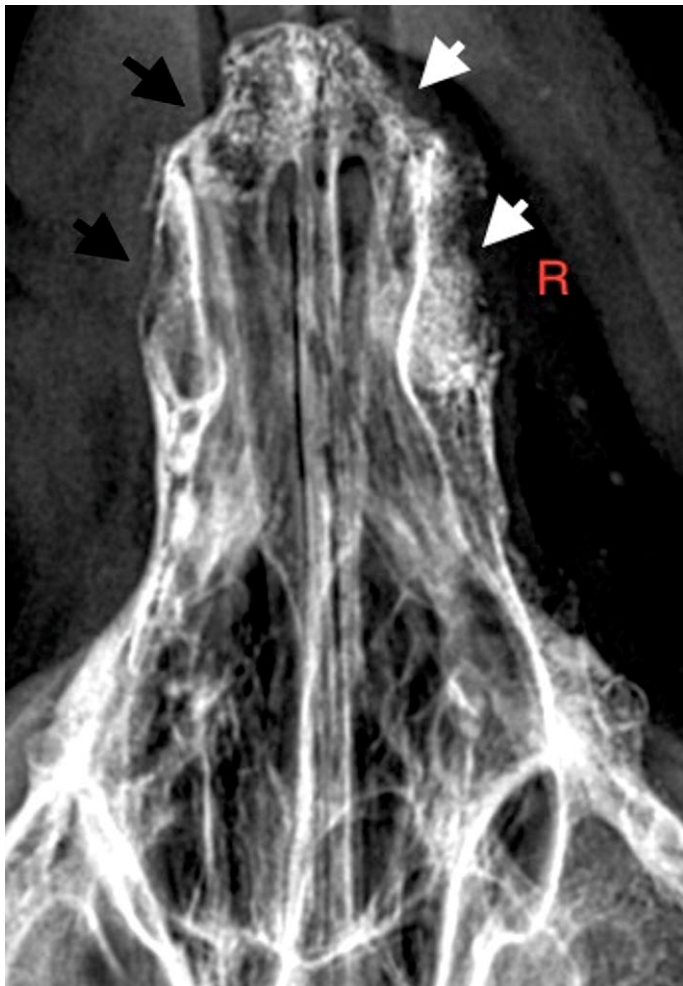


Fig. 8. The condition of the alveoli 8 weeks after surgery. Bone-filled alveoli with a predominance of bone on the right side without features of bone recession. The state of recession can be seen particularly well by comparing incisor and canine cavities on the right (white arrows) and left sides (black arrows)

Since the balance depends on the relative mass of the two edges, the buccal wall, due to its structure, will give way under the tension of the granulation tissue and begin to undergo gradual lysis (30). In the context of alveolar wound healing, the site of generating cell contraction force in the post-extraction wound is of great importance: it stabilizes the wound and serves as a matrix for bone formation (18, 31). In dentistry, a small percentage of cases involve an alveolar wound that has all four walls necessary for spontaneous bone healing. According to Vogel et al, the absence of one of the alveolar walls can result in impaired alveolar healing (35). Due to the loss of alveolar structure, there is also a loss of alveolar function, and this results in partial or complete resorption of the buccal alveolar bone wall after tooth extraction (13).

In dogs, post-extraction alveolar protection is most important in small and miniature breeds. In miniature breeds, periodontal disease occurs at a young age and often requires numerous extractions. The thickness of the alveolar bone in these dogs is often about 1-1.5 cm in height of the entire mandibular alveolar bone. Considering the vertical bone recession of 11-22% shown above, one should expect about 0.8-1.3 cm of vertical bone in such a patient. Year after year, this atrophy will progress. With such extensive atrophy of the alveolar bone, extraction in a young dog of a small or miniature breed may result at a later time in complete atrophy of the mandibular bone and thus impaired food intake and chewing, as well as related problems (7, 28). In extreme cases, feeding an animal through a probe or by the owner may be necessary, as it will be impossible for the dog to take food from the bowl independently.

In medium and large breed dogs, this problem is not as severe, as the bone (especially of the mandible) in every dimension (height, width and thickness) is much larger than in miniature breeds. As a result, even at the highest percentage of bone atrophy, there will be no risk of jaw fracture. In medium and giant breeds, securing the post-extraction alveolus in periapical lesions presents a challenge. The removal, in particular, of such large teeth as the fang, the first molar of the mandible or the last premolar of the maxilla without protecting the alveolus with bone-replacement material can result in the formation of an oronasal fistula or impaired healing of the alveolus with the formation of a large amount of granulation tissue. Finding the simplest ways to protect the alveolar bone from atrophy and methods of bone restoration is therefore a key topic that modern veterinary dentistry needs to focus on.

Available literature data extensively describes various methods of filling post-extraction alveoli (14, 20, 21). In the present study, we considered the two most popular ways: the use of collagen sponge and hydroxyapatite in a polymeric form.

The main function of the collagen sponge is to have a haemostatic effect and to hold the clot in the alveolus

to prevent post-extraction complications, including impaired healing of the alveolus or the formation of a so-called dry alveolus. It is, however, not sufficient in the healing process especially in large alveoli, where the forces acting on the alveolus are greater than the compensatory forces of the absorbable material collagen sponge. The clot undergoes remodelling into granulation tissue in a short period of time, and this can contribute to alveolar remodelling, fibrous tissue ingrowth and destructive effects on the alveolar bone (6, 8).

Hinz B. et al. in a 2001 study demonstrate its indirect effect on the structural and mechanical support of the surrounding tissues by releasing tension in the coronal part of the wound, thereby blocking premature tissue collapse in the first phase of healing (12, 34). Hydroxyapatite is one of the best studied biomaterials in both human and veterinary medicine (37, 38).

With multiple or deep alveolar bone defects, as well as in patients with a thin periodontal biotype, not only dimensional changes in bone but also soft tissue recession may occur (22). According to Rothamel et al., the right choice for treatment therefore appears to be to protect the alveoli with bone substitute material, which has a positive effect on bone healing and prevents atrophy of peripheral alveolar bone fragments (25). The use of pure hydroxyapatite does not seem to be a good solution, as the increased amount of hydroxyapatite in the implant material decreases the degradation rate of the material as mentioned by Jung B. T. et al. Hence, it is necessary to use materials that contain a combination of hydroxyapatite with polymers or bioceramics, which significantly improve their osteoinductive properties that promote cell proliferation (15). The available literature data show significant advantages of assimilating biodegradable materials, e.g. no scarring or hardening of the tissues around the implant, no risk of material rejection, full biocompatibility and reduced healing time. A detailed comparison of combinations of hydroxyapatite with substances intended to improve its properties was presented in their study by Rajewska J. et al. The data presented by the authors shows that biodegradable polymers can therefore be successfully used instead of conventional materials, depending on the properties needed in a particular case. Lactide polymers play a significant role in the future of bone regeneration due to their ease, cheapness and ethics of maintenance as well as their processability (24).

The innovation of combining the two components into a composite comprises carrying out curdlan into a triple helix structure: a conformation that does not stimulate pro-inflammatory processes and allows trapping of hydroxyapatite granules. It has proven biocompatible, able to stimulate bone growth through direct action on osteoblasts, non-toxic, and having properties that minimize inflammation through the use of the sugar polymer curdlan (2, 3). It is also worth

noting that it is the only formulation available on the market that takes on a plastic form after soaking, so it can be easily moulded and fit three-dimensionally into the alveolus. The standard bone healing time reported in the literature assumes healing within 8 weeks (27, 36). In this study, it was assumed that alveoli that were not implanted with FlexiOss®Vet, but filled with the routinely used Surgispon collagen sponge, would also be healed in 8 weeks, allowing a comparison between the two methods. Our study shows radiologically that the alveolus is filled with bone as early as 21 days after tooth extraction. This demonstrates accelerated osteogenesis based on the placed FlexiOss®Vet bone substitute material as early as week 3 of the study.

The study conducted, on one hand, is particularly aimed at drawing attention to the frequently overlooked problem of alveolar healing in dogs. After tooth extraction, often no thought is given to alveolar bone in dogs in the long-term context and the consequences of not protecting the alveolus especially in small and miniature breeds of dogs. Hydroxyapatite in human dentistry is widely used particularly in periodontics and implantology (9). Publications relating to this topic indicate that there is no „gold standard” for alveolar preservation, and none of the techniques used so far are able to completely stop bone resorption. However, studies reporting on the use of hydroxyapatite note reduced alveolar bone resorption and better soft tissue behaviour, including keratinization in the post-extraction wound healing process. Considering the correlation between bone quality and quantity, there is a distinct advantage of using hydroxyapatite over collagen sponge (32).

The results of the study show that the formation of new bone in the alveolus after implantation of the polymeric formulation of hydroxyapatite (FlexiOss®Vet) is faster (21 days) than when the alveolus is protected with only collagen sponge (56 days). On macroscopic examination, there are noticeable differences between alveoli in which cavities were replaced with newly formed bone on the basis of FlexiOss®Vet, compared to alveoli filled with Surgispon, in which granulation was formed, and the process of bone reconstruction was much slower. There were no post-operative complications in areas with implanted bone substitute material.

Thus, the observations show that the scaffold built on the basis of FlexiOss®Vet provides suitable conditions for osteogenesis while inhibiting the forces that cause lysis of the buccal alveolar wall. It can be concluded that it could also serve as an ideal way to fill large bone defects even in bones affected by severe inflammation associated with periodontal disease, along with concomitant anti-inflammatory therapy. Reducing bone resorption with a hydroxyapatite framework is a modern, minimally invasive and promising concept.

References

1. Barone A., Aldini N. N., Giardino R., Guirando J. L. C., Covani U.: Xenograft versus extraction alone for ridge preservation after tooth removal: a clinical and histomorphometric study. *J. Periodontol.* 2003, 79, 1370-1377.
2. Belcarz A., Ginalska G., Slosarczyk A., Paszkiewicz Z.: International Patent No 2421570 B1, Eur. Pat. Bull. 09/2015.
3. Belcarz A., Ginalska G., Pycka T., Zima A., Slosarczyk A., Polkowska I., Paszkiewicz Z., Piekarczyk W.: Application of β -1,3-glucan in production of ceramics-based elastic composite for bone repair. *Cent. Eur. J. Biol.* 2013, 8, 534-548.
4. Boyne P. J., Piaski N. R.: Secondary bone grafting of residual alveolar and palatal clefts. *J. Oral. Surg.* 1972, 30 (2), 87-92.
5. Camargo P. M., Lekovic V., Weinlaender M., Kolkkevold P. R., Kenney E. B., Dimitrijevic B., Nedic M., Jancovic S., Orsini M.: Influence of bioactive glass on changes in alveolar process dimensions after endodontia. *Oral Surgery, Oral Medicine, Oral Pathology, Oral Radiology and Endodontics* 2000, 90, 581-586.
6. Covani U., Ricci M., Bozzolo G., Mangano F., Zini A., Barone A.: Analysis of the pattern of the alveolar ridge remodelling following single tooth extraction. *Clin. Oral Implants Res.* 2011, 22, 820-895.
7. Cui L., Liu B., Liu G., Zhang W., Cen L., Sun J., Yin S., Liu W., Cao Y.: Repair of cranial bone defects with adipose derived stem cells and coral scaffold in a canine model. *Biomaterials* 2007, 28 (36), 5477-5486.
8. Discepoli N., Vignoletti F., Laino L., de Sanctis M., Munoz F., Sanz M.: Early healing of the alveolar process after tooth extraction. An experimental study in the beagle dogs. *J. Clin. Periodontol.* 2013, 40, 638-644.
9. Enemark H., Sindet-Pedersen S., Bundgaard M.: Long-term results after secondary bone grafting of alveolar clefts. *J. Oral Maxillofac. Surg.* 1987, 45 (11), 913-918.
10. Esteban S. L., Suarez T. R., Betegon F. E., Pecharroman C., Moya J. S.: Mechanical properties and interfaces of zirconia/nickel in micro- and nano-composites. *J. Mater. Sci.* 2006, 41, 5194-5199.
11. Hinz B., Mastrangelo D., Iselin C. E.: Mechanical tension controls granulation tissue contractile activity and myofibroblast differentiation. *Am. J. Pathol.* 2001, 159, 1009-1020.
12. Holmstrom S. E.: Veterinary Dentistry in Senior Canines and Felines. *Veterinary Clinics of North America: Small Animal Practice* 2012, 42 (4), 793-808.
13. Horowitz R., Holtzclaw D., Rosen P. S.: A review on alveolar ridge preservation following tooth extraction. *J. Evidence-Based Dental Practice* 2012, 12, 149-160.
14. Jang S. J., Kim S. E., Han T. S., Son J. S., Kang S. S., Choi S. H.: Bone regeneration of hydroxyapatite with granular Form or Porous Scaffold in Canine Alveolar Socket. *In Vivo* 2017, 31, 335-341.
15. Jung B. T., Kim W. H., Park B., Lee J. H.: Biomechanical evaluation of unilateral subcondylar fracture of the mandible on the varying materials: A finite element analysis. *PLoS One* 2020, 15.
16. Lekovic V., Kenney E. B., Weinlaender M., Han T., Klokkevold P., Nedic M., Orsini M.: A bone regenerative approach to alveolar ridge maintenance following tooth extraction. Report of 10 cases. *J. Periodontol.* 1997, 68, 563-570.
17. Lian J. B., Stein G. S.: Concepts of osteoblast growth and differentiation: basis for modulation of bone cell development and tissue formation. *Crit. Rev. Oral. Biol. Med.* 1992, 3 (3), 269-305.
18. Mohammadi H., Janney P. A., McCulloch C. A.: Lateral boundary mechanosensing by adherent cells in a collagen gel system. *Biomaterials* 2014, 35, 138-149.
19. Mooney M., Siegel M.: Animal models for bone tissue engineering of critical-sized defects (CSDs), bone pathologies, and orthopedic disease states, [in:] Hollinger J., Einhorn T., Doll B.: *Bone Tissue Engineering*. 1st ed. CRC Press, USA 2005, 217-244.
20. Murugan R., Ramakrishna S.: Bioresorbable composite bone paste using polysaccharide based nano hydroxyapatite, *Biomaterials* 2004, 25, 3829-3835.
21. Ohba S., Sumita Y., Nakatani Y., Noda S., Asahina I.: Alveolar bone preservation by a hydroxyapatite/collagen composite material after tooth extraction. *Clin. Oral. Invest.* 2019, 23, 2413-2419.
22. Pietrokovski J., Massler M.: Alveolar ridge resorption following tooth extraction. *J. Prostet. Dent.* 1967, Jan 17 (1), 21-27.
23. Porter A. E., Botehlo C. M., Lopes M. A.: Santos comparison of dissolution and apatite precipitation on hydroxyapatite and silicon-substituted hydroxyapatite in vitro and in vivo. *J. Biomed. Mater. Res. A.* 2004, 69, 670-679.
24. Rajewska J., Kowalski J., Matys J., Dobrzyński M., Wiglusz R. J.: The use of Lactide Polymers in Bone Tissue Regeneration in Dentistry – A systematic Review. *J. Funct. Biomater.* 2023, 14, 83.
25. Rothamel D., Schwarz F., Herten M., Engelhardt E., Donath K., Kuehn P., Becker J.: Dimensional ridge alterations following socket preservation using a nanocrystalline hydroxyapatite paste: a histomorphometrical study in dogs. *Int. J. Oral. Maxillofac Surg.* 2008 37, 741-747.
26. Sbordone C., Toti P., Martuscellim R., Guidetti F., Ramaglia L., Sbordone L.: Retrospective volume analysis of bone remodeling after tooth extraction with and without deproteinized bovine bone mineral insertion. *Clin. Oral. Implants. Res.* 2016, 27, 1152-1159.
27. Schropp L., Wenzel A., Kostopoulos L., Karring T.: Bone healing and soft tissue contour changes following single-tooth extraction: a clinical and radiographic 12 month prospective study. *Int. J. Periodont. Res. Dent.* 2003, 23, 313-323.
28. Schropp L., Wenzel A., Kostopoulos L., Karring T.: Bone healing and soft tissue contour changes following single-tooth extraction: a clinical and radiographic 12-month prospective study. *Int. J. Periodont. Res. Dent.* 2003, 23, 313-323.
29. Sopyan I., Mel M., Ramesh S., Khalid K. A.: Porous hydroxyapatite for artificial bone applications. *Sci. Tech. Adv. Mater.* 2007, 8, 116-123.
30. Steiner G. G., Francis W., Burell, Kallet M. P., Steiner D. M., Macias R.: The healing socket and socket regeneration. *Comped. Contin. Educ. Dent.* 2008, 29, 2-11.
31. Street J., Winter D., Wang J. H., Wakai A., McGuinness A., Redmond H. P.: Is human fracture hematoma inherently angiogenic? *Clin. Ortop. Relat. Res.* 2000, 378, 224-237.
32. Stumbras A., Kuliesius P., Januzis G., Juodzbalys G.: Alveolar ridge preservation after tooth extraction using different Bone Graft Materials and Autologous Platelet Concentrates: a systematic review. *J. Oral. Maxillofac. Res* 2019, 10 (1).
33. Sudo A., Hasegawa M., Fukuda A., Uchida A.: Treatment of infected hip arthroplasty with antibiotic-impregnated calcium hydroxyapatite. *J. Arthroplasty.* 2008, 23, 145-150.
34. Tomasek J. J., Gabbiani G., Hinz B., Chaponnier C., Brown R. A.: Myofibroblasts and mechano-regulation of connective tissue remodelling. *Nat. Rev. Mol. Cell. Biol.* 2002, 3, 349-363.
35. Vogel V., Sheetz M.: Local force and geometry sensing regulate cell functions. *Nat. Rev. Mol. Cell. Biol.* 2006, 7, 265-275.
36. Wallis C., Marshall M., Colyer A., O'Flynn C., Deusch O., Harris S.: A longitudinal assessment of changes in bacterial community composition associated with the development of periodontal disease in dogs. *Vet. Microbiol.* 2015, 181 (3-4), 271-282.
37. Yoshikawa T., Ohgushi H., Tamai S.: Immediate bone forming capability of prefabricated osteogenic hydroxyapatite. *J. Biomed. Mater. Res.* 1996, 32 (3), 481-492.
38. Yoshioka M., Tanimoto K., Tanne Y., Sumi K., Awada T., Oki N., Sugiyama M., Kato Y., Tanne K.: Bone regeneration in artificial jaw cleft by use of carbonated hydroxyapatite particles and mesenchymal stem cells derived from iliac bone. *Int. J. Dent.* 2012, 352-510.

Corresponding author: Anna Misztal-Kunecka, Veterinary Clinic DentalVet Anna Misztal-Kunecka, Szczecin, Poland; e-mail: dentalvet.misztal@gmail.com

Anna Lojszczyk: e-mail: anna.lojszczyk@gmail.com

Stanisław Dzimira: e-mail: stanislaw.dzimira@upwr.edu.pl